

Evaluation of anterior capsule opening and predicted refractive error in patients with pseudoexfoliation and primary open angle glaucoma following cataract surgery

Numan Eraslan¹, İlker Kocamis¹

ABSTRACT

Purpose: To compare the vertical and horizontal diameters of capsulorhexis in patients with pseudoexfoliative glaucoma (PEXG) and primary open-angle glaucoma (POAG) who underwent cataract surgery, and to evaluate the effect of anterior capsular opening on predicted refractive error.

Materials and Methods: This single center case-control study included 53 glaucoma patients. All patients underwent detailed ophthalmic examination and phacoemulsification + intraocular lens (IOL) surgery. Furthermore, all examinations and surgeries were performed by the same physician. The glaucoma patients were then stratified into two groups according to their glaucoma diagnosis. The PEXG group consisted of 28 patients and the POAG group consisted of 25 patients. Finally, the vertical and horizontal capsulorhexis diameters of all patients were measured using slit-lamp biomicroscopy at 6 months postoperatively.

Results: Preoperatively, there were no differences between the two groups with respect to age, sex, cataract grade, intraocular pressure, axial length, central corneal thickness, anterior chamber depth, lens thickness, and white-to-white distance. In addition, at six months postoperatively, the two groups were similar in terms of surgically induced astigmatism, IOL power, spherical/aspherical IOL ratio, spherical equivalents, and predicted refractive error. However, the diameters of both the horizontal and vertical capsulorhexis were smaller in the PEXG group as compared to the POAG group.

Conclusion: Despite the challenges caused by the anterior capsule and weak zonules in PEXG patients, when we performed a central capsulorhexis with vertical and horizontal diameters between 4.8 and 5.5 mm, the predictive refractive error was similar to the POAG group.

Keywords: Anterior capsulorhexis diameters, phacoemulsification, predictive refractive error, primary open-angle glaucoma, pseudoexfoliative glaucoma.

INTRODUCTION

Cataract surgery is one of the most commonly performed procedures in ophthalmology, and it provides significant visual benefits to patients with cataracts. However, pseudoexfoliation glaucoma (PEXG) poses significant challenges to cataract surgery due to its underlying pathophysiological changes.^{1,2} PEXG is characterized by the accumulation of abnormal fibrillary material in the eye, resulting in impaired trabecular meshwork function and

elevated intraocular pressure (IOP). In addition, due to the zonular weakness caused by the pseudoexfoliation (PEX) material accumulated in the zonules, it is tough to perform the continuous curvilinear capsulorhexis (CCC) procedure in an accurate size and centralized manner during surgery in PEXG patients. Therefore, a crucial aspect that requires close examination in cataract surgery for PEXG patients is the anterior capsule opening (ACO).³⁻⁵ Finally, the size and integrity of the ACO are key factors for surgical success and postoperative visual outcomes. A well-centered and

1-MD, University of Health Sciences Dışkapı Yıldırım Beyazıt Training and Research Hospital, Ankara, Türkiye

Received: 09.09.2023

Accepted: 21.01.2024

TJ-CEO 2024; 19: 147-152

DOI: 10.37844/TJ-CEO.2024.19.20

Correspondence author:

Numan Eraslan

Email: numaneraslan@hotmail.com

Copyright © 2024 The author(s). This is an open-access article under the terms of the [Creative Commons Attribution License \(CC BY\)](https://creativecommons.org/licenses/by/4.0/) which permits unrestricted use, distribution, and reproduction in any medium or format, provided the original work is properly cited.

adequately sized capsulorhexis can assist with optimal positioning of the intraocular lens (IOL) and minimize the risk of postoperative complications, such as capsular phimosis and IOL dislocation.⁶

Another essential factor affecting visual outcomes following cataract surgery in PEXG patients is the predicted refractive error. Achieving the desired refractive outcome is critical for patient satisfaction and visual rehabilitation. However, the presence of PEX material and associated zonular weakness can complicate the calculation of IOL power and make it more difficult to achieve an accurate postoperative refraction.^{7,8} In light of these considerations, this study aims to evaluate the ACO alterations after cataract surgery for PEXG and primary open-angle glaucoma (POAG) patients. Additionally, it seeks to analyze the accuracy of predicted refractive error outcomes in this particular population.

MATERIALS AND METHODS

This was a retrospective, single-center, case-control study. The University of Health Sciences Ethics Committee approved the study undertaken at the Diskapi Yildirim Beyazit Training and Research Hospital, which was conducted in compliance with the Helsinki Declaration. All subjects were recruited over six years between March 2016 and June 2022 from the Diskapi Glaucoma Clinic Registry (Ethics committee approval number: 2022-139/08).

This study included a total of 53 eyes of 28 patients with PEXG and 25 patients with POAG (as a control group), who underwent uncomplicated phacoemulsification + IOL surgery for cataract diagnosis between March 2016 and June 2022. On the other hand, patients having zonular dialysis, pupil too small to require the use of an iris hook, uncontrolled elevation of IOP, retinal disease, a history of ocular trauma, previous ocular surgeries, axial length less than 20 mm, and greater than 25 mm were excluded from the study. Additionally, patients who encountered any intraoperative complications, including peripheral capsulorhexis tear, posterior capsule rupture, and corneal suturing among others, were also excluded.

Preoperatively, all patients underwent a comprehensive ophthalmic examination including visual acuity, slit-lamp biomicroscopy, IOP measurement by Goldmann applanation tonometry, iridocorneal angle measurement with Goldmann three-mirror lens, and dilated funduscopy. Patients were defined as having PEXG or POAG based on the guidelines of the European Glaucoma Society.⁹

Furthermore, the cup-to-disc ratio was determined through dilated funduscopy examination. In addition, automated perimetry measurement (24-2 Swedish Interactive Threshold Algorithm (SITA)-Fast test) was performed using Humphrey Field Analyzer (Carl Zeiss Meditec Inc.). According to Hodapp-Parrish-Anderson criteria, glaucoma patients were categorized as mild (mean deviation (MD): ≥ -6 dB), moderate (MD: -6.01 to -12 dB), and advanced (MD: < -12 dB).¹⁰ Retinal nerve fiber layer thickness (RNFL) measurement using Fourier-domain OCT (RTVue-XR 100 Avanti, Optovue, Inc. Fremont, CA, USA) was also performed for each patient. Moreover, IOL power calculations were executed using the optical biometry device Lenstar LS 900 (Haag-Strait AG, Switzerland) and the SRK-T formula. The same device was used to measure axial length, central corneal thickness (CCT), anterior chamber depth, lens thickness, and white-to-white length. Cataract stiffness of the patients was graded according to a specific classification system.¹¹

All surgeries were performed by the same surgeon (NE) using the Centurion phacoemulsification device (Alcon, Fort Worth, TX) as follows: A 2.2 mm incision was made for all patients. The main entrance incision was aligned with the perpendicular axis. After filling the anterior chamber with viscoelastic material, all patients underwent centralized capsulorhexis with a diameter of 5.00-5.50 mm. The Acrysoft SA60 AT spherical IOL (Alcon, Fort Worth, TX) and Alcon IQ (Alcon, Fort Worth, TX) and Sensar AAB00 (Johnson & Johnson Vision) aspheric IOLs were used for patients. In the sixth postoperative month, the pupils of the patients were dilated and the diameters

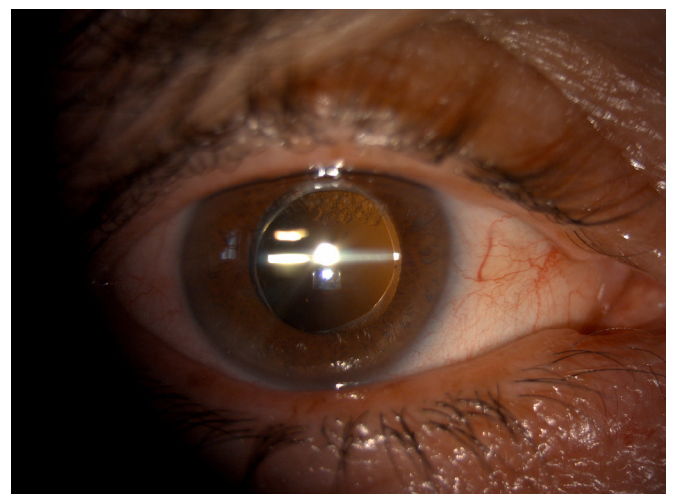


Figure 1: Measurement of the horizontal diameter of the anterior capsulorhexis using a slit lamp biomicroscope.

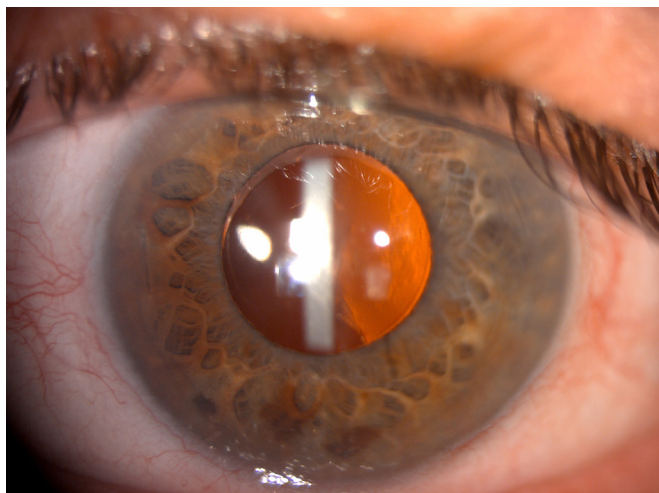

Figure 2: Measurement of the vertical diameter of the anterior capsulorhexis using a slit lamp biomicroscope.

of the capsulorhexis were measured horizontally and vertically using a slit lamp biomicroscope (Figure 1 and 2). The Alpine method was used for the calculation of surgically induced astigmatism. (http://www.drpeyman.ir/Ophthalmology_Calculator.htm).

Statistical analysis

Parameters of the PEXG and POAG groups were compared

using the Independent-Samples T-test, Pearson Chi-Square test, and Mann-Whitney U tests. SPSS 21 (SPSS Inc., Chicago, IL, USA) was used for statistical analyzes. Results with a p-value less than 0.05 were considered statistically significant.

RESULTS

There was no difference between two groups regarding age and sex. There were statistically no significant differences in cataract grades, glaucoma stage, MD, RNFL, cup-to-disc ratio, IOP, axial length, CCT, anterior chamber depth, lens thickness, and white to white distance between two groups preoperatively. Detailed results are demonstrated in (Table 1).

At the postoperative six months, two groups were similar when mean surgically induced astigmatism, IOL power, spheric/aspheric IOL percentage, spherical equivalents, and predicted refractive error were compared. The horizontal and vertical capsulorhexis diameters of the PEXG group were smaller than those of the POAG group ($p=0.002$, $p=0.005$, respectively) (Table 2). There were no capsular phimosis, severe posterior capsular opacification, zonular dialysis, and IOL dislocation in any of the groups.

Table 1: Preoperative values between groups

Data	POAG	PEXG	P Value
Age	70.1 ± 5.8	70.6 ± 5.9	0.729*
Sex (female/male)	13/12	15/13	0.909**
Cataract Grade (G2+G3/G4)	17/8	16/12	0,416**
Glaucoma stage (mild/moderate)	18/7	15/13	0,167**
MD (decibel)	5.01 ± 2.99	6.53 ± 2.88	0.051***
RNFL (µm)	84.64 ± 7.19	82.42 ± 7.65	0.190***
Cup/Disc Ratio	0.48 ± 0.11	0.53 ± 0.1	0.065***
Intraocular Pressure (mmHg)	13.9 ± 2.4	15.1 ± 3.6	0.197*
Axial Length (mm)	23.39 ± 0.68	23.21 ± 0.81	0.411*
Central Corneal Thickness (µm)	532.92 ± 21.41	536.29 ± 45.04	0.739*
Anterior Chamber Depth (mm)	3.35 ± 0.40	3.27 ± 0.41	0.478*
Lens Thickness (mm)	4.36 ± 0.36	4.33 ± 0.47	0.819*
WTW Length (mm)	11.94 ± 0.37	11.85 ± 0.36	0.382**

MD, mean deviation; PEXG, pseudoexfoliation glaucoma; POAG, primary open-angle glaucoma; RNFL, retinal nerve fiber layer thickness; WTW, white-to-white; mm, millimeter; µm, mikrometer; mmHg, millimeters of mercury.

P*: Independent-Samples T-test

P**: Pearson Chi-Square test

P***: Mann Whitney-U test

Table 2: Postoperative 6th month values between groups

Data	POAG	PEXG	P Value
SIA (Diopter)	0.43 ± 0.15	0.49 ± 0.15	0.129*
Intraocular Lens (Spherical/Aspheric)	17/8	14/14	0,184**
Intraocular Lens Power	21.66 ± 1.35	22.07 ± 1.66	0.331*
Spherical Equivalent (Diopter)	-0.43 ± 0.47	-0.41 ± 0.45	0.881*
Predicted Refractive Error (Diopter)	-0.11 ± 0.38	-0.12 ± 0.42	0.831***
Horizontal Capsulorhexis Diameter (mm)	5.29 ± 0.16	5.14 ± 0.12	0.002***
Vertical Capsulorhexis Diameter (mm)	5.16 ± 0.17	5.04 ± 0.13	0.005*

PEXG, pseudoexfoliation glaucoma; POAG, primary open-angle glaucoma; SIA, Surgically induced astigmatism; mm, milimetre
P*: Independent-Samples T-test
P**: Pearson Chi-Square test
P***: Mann Whitney-U test

DISCUSSION

In this study, a total of 53 eyes from 28 PEXG patients and 25 POAG patients were included, all of whom underwent phacoemulsification + IOL surgery. The exclusion criteria were rigorously applied to ensure a homogeneous sample, and the surgeries were performed by the same surgeon to mitigate potential variability. The utilization of consistent IOL models and the similarity of the spheric/aspheric IOL distribution between the groups further enhanced the reliability of the results. Analysis of preoperative characteristics revealed no statistically significant differences between the PEXG and POAG groups in terms of age, sex, cataract grades, IOP, glaucoma stage, RNFL, cup-to-disc ratio, axial length, CCT, anterior chamber depth, lens thickness and white-to-white distance. This similarity in baseline characteristics helps establish a solid foundation for meaningful comparisons between the two glaucoma types.

One of the remarkable findings of this study pertains to the size of capsulorhexis diameters. It was observed that the PEXG group exhibited smaller horizontal and vertical capsulorhexis diameters compared to the POAG group. This observation raises important questions about the underlying factors driving these differences. Potential anatomical variations associated with PEXG might play a role in this outcome. In a prospective randomized clinical trial, increased apoptosis and decreased proliferation within the lens epithelial cells on the anterior capsules of the cataract patients with PEX were revealed.¹² In another study, it was demonstrated that the anterior lens capsule

was thicker than normal in PEX syndrome using high resolution optical coherence tomography imaging.¹³ The implications of such variations could be multifaceted, including the potential impact on postoperative visual outcomes, potential complications, and the broader surgical experience for both patients and surgeons. The size and centration of the capsulorhexis directly influence the stability and positioning of the IOL, which in turn can have a profound impact on patient postoperative visual acuity and overall satisfaction. In a prospective study, it was indicated that PEX syndrome plays an important role in the reduction of ACO in dislocated lenses after cataract surgery.¹⁴ In our study, no complications related to anterior capsule size differences were observed. The disparities in capsulorhexis size observed in this study underscore the need for further investigation into the optimal sizing strategies for different glaucoma types and potentially for different ocular anatomies. Prospective studies examining the long-term visual outcomes and complications associated with varying capsulorhexis sizes would provide invaluable insights.

Studies on ACO after cataract surgery in non-compromised eyes demonstrate a reduction of around 10-15% in the opening area during the first six post-operative months. All these studies utilized a CCC with a diameter ranging from 4.5 to 5.5 mm.¹⁵⁻¹⁷ In contrast, Hayashi and colleagues found increased ACO contraction in high-risk eyes. Their study included cataract surgery patients with primary angle closure, PEX syndrome, or diabetic retinopathy. They observed an average reduction of 8-16% in the first month after surgery, 18-29% in the third month, and 17-30%

in the sixth month.⁶ These findings align with previous research by the same authors. In cases of PEX syndrome, the reduction of ACO was 17.5% at one month and 23.9% at six months.³ Additionally, the zonular weakness resulting from PEX material makes it more challenging to achieve an optimally sized CCC during surgery in patients diagnosed with PEXG.¹⁴ In our study, horizontal and vertical capsulorhexis diameters were smaller in the PEXG group than in the POAG group at 6 months postoperatively, consistent with the literature. However, capsular phimosis, severe posterior capsular opacity and IOL dislocation were not observed in PEXG patients despite their small capsulorhexis diameter. Therefore, we recommend that the mean diameter of the CCC in PEXG patients should be greater than 5 mm at 6 months postoperatively. To attain this goal, it is essential to consider the reduction in the diameter of the capsulorhexis among PEXG patients, which can range from 8-16% after six months following the surgery. Finally, studies conducted in the literature demonstrate that there is no considerable statistical decrease in ACO after three months following surgery, for both typical cataract patients and those with PEX syndrome.^{3,15,18} However, the patient follow-up in these three literature studies lasted a maximum of one year, which is relatively brief. Thus, further studies with longer follow-up periods are necessary to obtain more comprehensive findings.

Another key aspect of the study's results is the predicted refractive error. The research demonstrated that both PEXG and POAG groups exhibited similar outcomes in terms of surgically induced astigmatism, intraocular lens power, spherical equivalents, and predicted refractive error. Consequently, Kassos et al. found that patients with PEX syndrome achieved a predicted refractive error similar to that of controls after cataract surgery.¹⁹ Contrary to this, Tekcan et al. suggested that patients with PEXG produced a higher mean absolute error compared to POAG and normal patients after cataract surgery.²⁰ They associated their result with deepening of the anterior chamber and a decrease in IOP after surgery. However, this correlation was only present in the Barret Universal II and Hill-RBF formulas. We only used the SRK-T formula and did not encounter any refractive prediction error difference between our groups. The finding is particularly relevant given the intricate nature of glaucoma and its potential impact on ocular structures and measurements. The harmonious refractive outcomes among the PEXG and POAG groups suggest that despite the underlying glaucoma type, cataract surgery can be tailored to yield predictable refractive results. This has significant implications for patient satisfaction and quality

of life after surgery, as refractive outcomes play a crucial role in visual rehabilitation.

Nonetheless, the study has certain limitations. Its retrospective design and relatively small sample size might limit the generalizability of the findings. Additionally, the inability to measure capsulorhexis diameter intraoperatively and the relatively short follow-up are other limitations of our study. Finally, it is challenging to draw any conclusions about patients with advanced glaucoma since all patients in the study were at the mild and moderate stages.

In conclusion, this study provides a valuable contribution to understanding the outcomes of cataract surgery in the context of PEXG and POAG. The disparities in capsulorhexis size and the consistent refractive outcomes are noteworthy takeaways that spark further inquiry. Future research endeavors should aim to elucidate the underlying anatomical, physiological, and clinical factors driving capsulorhexis size differences, and their impact on postoperative outcomes. Ultimately, by deepening our understanding of these intricate nuances, we can improve the precision and success of cataract surgery for patients with glaucoma, ultimately improving their visual outcomes and overall quality of life.

Disclaimer on financial support (grants): None

Conflicts of Interest: The authors report no financial support or financial conflicts of interest. The authors have reported no financial relationship with any company and no external funding.

Ethical approval: All procedures performed in studies involving human participants were in accordance with the ethical standards of the institutional and/or national research committee and with the Helsinki Declaration of 1964 and its subsequent amendments or comparable ethical standards.

REFERENCES

1. Naumann GO, Schlötzer-Schrehardt U, Kühle M. Pseudoexfoliation syndrome for the comprehensive ophthalmologist. Intraocular and systemic manifestations. *Ophthalmology* 1998;105:951-68. [https://doi.org/10.1016/S0161-6420\(98\)96020-1](https://doi.org/10.1016/S0161-6420(98)96020-1)
2. Elgin U, Şen E, Şimşek T, et al. Early postoperative effects of cataract surgery on anterior segment parameters in primary open-angle glaucoma and pseudoexfoliation glaucoma. *Turk J Ophthalmol* 2016;46:95-8. <https://doi.org/10.4274/tjo.92604>

3. Hayashi H, Hayashi K, Nakao F, et al. Anterior capsule contraction and intraocular lens dislocation in eyes with pseudoexfoliation syndrome. *Br J Ophthalmol* 1998;82:1429-32. <https://doi.org/10.1136/bjo.82.12.1429>
4. Yaz Y, Yıldırım N, Aydın Yaz Y, et al. Three single nucleotide polymorphisms of LOXL1' in a Turkish population with pseudoexfoliation syndrome and pseudoexfoliation glaucoma. *Turk J Ophthalmol* 2018;48:215-20. <https://doi.org/10.4274/tjo.83797>
5. Yüksel N, Yılmaz Tuğan B. Pseudoexfoliation glaucoma: Clinical presentation and therapeutic options. *Turk J Ophthalmol* 2023;53:247-56. <https://doi.org/10.4274/tjo.galenos.2023.76300>
6. Hayashi K, Yoshida M, Hirata A, et al. Anterior capsule relaxing incisions with neodymium: YAG laser for patients at high-risk for anterior capsule contraction. *J Cataract Refract Surg* 2011;37:97-103. <https://doi.org/10.1016/j.jcrs.2010.07.027>
7. Belov DF, Potemkin VV, Nikolaenko VP. Optimization of intraocular lens power calculation in pseudoexfoliation syndrome. *Vestn Oftalmol* 2021;137:38-42. <https://doi.org/10.17116/oftalma202113704138>
8. Sen E, Kocabas D, Elgin U, et al. Early refractive effect of cataract surgery in medically controlled glaucoma. *Journal of Glaucoma and Cataract* 2022;17:95-100. <https://doi.org/10.37844/glauc.cat.2022.17.15>
9. European Glaucoma Society Terminology and Guidelines for Glaucoma, 4th Edition - Chapter 2: Classification and terminology Supported by the EGS Foundation. *Br J Ophthalmol* 2017;101:73-127. <https://doi.org/10.1136/bjophthalmol-2016-EGSguideline.002>
10. Susanna R, Vessani RM. Staging glaucoma patient: why and how? *Open Ophthalmol J* 2009;3:59-64. <https://doi.org/10.2174/1874364100903020059>
11. Chylack LT, Wolfe JK, Singer DM, et al. The lens opacities classification system III. The longitudinal study of cataract study group. *Arch Ophthalmol* 1993;111:831-6. <https://doi.org/10.1001/archopht.1993.01090060119035>
12. Turan G, Turan M. The evaluation of TUNEL, PCNA and SOX2 expressions in lens epithelial cells of cataract patients with pseudoexfoliation syndrome. *Curr Eye Res* 2020;45:12-6. <https://doi.org/10.1080/02713683.2019.1657463>
13. Batur M, Seven E, Tekin S, et al. Anterior lens capsule and iris thicknesses in pseudoexfoliation syndrome. *Curr Eye Res* 2017;42:1445-9. <https://doi.org/10.1080/02713683.2017.1338349>
14. Vanags J, Erts R, Laganovska G. Anterior capsulorhexis opening reduction after cataract surgery with subluxated lenses. *Medicina (Kaunas)* 2017;53:310-5. <https://doi.org/10.1016/j.medic.2017.10.003>
15. Hayashi K, Hayashi H, Nakao F, et al. Reduction in the area of the anterior capsule opening after polymethylmethacrylate, silicone, and soft acrylic intraocular lens implantation. *Am J Ophthalmol* 1997;123:441-7. [https://doi.org/10.1016/s0002-9394\(14\)70169-2](https://doi.org/10.1016/s0002-9394(14)70169-2)
16. Sickenberg M, Gonvers M, van Melle G. Change in capsulorhexis size with four foldable loop-haptic lenses over 6 months. *J Cataract Refract Surg* 1998;24:925-30. [https://doi.org/10.1016/s0886-3350\(98\)80044-8](https://doi.org/10.1016/s0886-3350(98)80044-8)
17. Corydon C, Lindholt M, Knudsen EB, et al. Capsulorhexis contraction after cataract surgery: comparison of sharp anterior edge and modified anterior edge acrylic intraocular lenses. *J Cataract Refract Surg* 2007;33:796-9. <https://doi.org/10.1016/j.jcrs.2007.01.020>
18. Park TK, Chung SK, Baek NH. Changes in the area of the anterior capsule opening after intraocular lens implantation. *J Cataract Refract Surg* 2002;28:1613-7. [https://doi.org/10.1016/s0886-3350\(02\)01378-0](https://doi.org/10.1016/s0886-3350(02)01378-0)
19. Kassos I, Tzamalīs A, Dermenoudi M, et al. Ocular parameter changes after phacoemulsification in pseudoexfoliative eyes: case-control study. *J Cataract Refract Surg* 2022;48:894-9. <https://doi.org/10.1097/j.jcrs.0000000000000885>
20. Tekcan H, Alpogan O, Imamoglu S. Pseudoexfoliation glaucoma as a predictor of refractive surprise after uneventful cataract surgery. *J Glaucoma* 2023;32:272-9. <https://doi.org/10.1097/IJG.0000000000002187>