

Simultaneous Bilateral Combined Micro Invasive Glaucoma Surgery (MIGS) with iStent inject® and Femtosecond Laser-assisted Cataract Surgery with Premium IOLs

Florian KRETZ¹, Ahmad MAQSOUTI¹, Claudia HERBERS¹

ABSTRACT

Our purpose was to show the visual outcome following iStent inject and Premium IOL implantation and to analyze the correlation between objective outcomes versus subjective outcomes and patient satisfaction.

We report a case of 64-year-old female patient, complaining of decreased visual acuity, seeing veil in her visual field and night driving difficulty. The patient had a history of normal tension glaucoma and cortical cataract in both eyes. Optic disc examination showed: mild cupping and RNFL loss bilaterally in both eyes. We implanted 2 iStent inject in each eye followed by a hydrophilic foldable one-piece multifocal acrylic IOL (Oculentis LS-313 MF-30) in OD and a hydrophilic one-piece enhanced depth of focus IOL (Oculentis LS-313 Comfort-MF 15) in OS. After an uneventful cataract surgery, the post-operative outcomes were as follows: The patient is not using any anti-glaucoma eye drops anymore, corrected distance visual acuity [logMAR] increased OD from 0,20 to -0,1 and OS from 0,00 to 0-,1 with a binocular visual acuity of -0,2. Even though the objective outcomes showed good functional results, but patient complained about out of focus vision in distance, with moderate halo while still realizing she can see everything.

Keyword: Normal tension glaucoma, Cataract, IOL, MIGS, FLACS.

INTRODUCTION

Innovation is defined as the introduction of something new. Ophthalmology and its subspecialties have been at the forefront of medical innovation and have embraced the rapid advances in various technologies, including pharmacology, imaging, data processing, and devices.¹ All these advancements are made to achieve the best post-treatment outcome, but sometimes we face surprises for which we have no explanation. For instance, in this case report, although we achieved excellent objective outcomes but the subjective responses from the patient were far away from our expectations.

Glaucoma and cataracts are two of the most common eye diseases affecting the aging population, with a large percentage of patients with coexistent pathology. Surgeons

and patients would prefer to resolve both issues in a single surgical setting; however, current approaches to combined cataract and glaucoma surgery have significant issues limiting their widespread use. Phacoemulsification surgery alone has been shown to help lower IOP, but often it is not sufficient. New advances in glaucoma management, however, are enabling the cataract specialist to assist patients on both fronts.²

Minimally invasive glaucoma surgeries (MIGS) have attracted significant attention, as they have been reported to lower intra-ocular pressure (IOP) and have an excellent safety profile. The iStent is an example of a minimally invasive glaucoma device that has received particular attention due to its early and wide spread utilization.³

The iStent inject® (Glaukos, Laguna Hills, Calif.) is

1- MD. FEBO, Augentagesklinik Rheine & Greven, Germany

Received: 20.12.2019

Accepted: 23.12.2019

Glo-Kat 2020; 15: 123-129

DOI: 10.37844/glauc.cat.2020.15.23

Correspondence Address:

Florian KRETZ

Augentagesklinik Rheine & Greven, Osnabrücker Str. 233-235
48429 Rheine, Germany

Phone: +49-5971-9825844

E-mail: mail@florian-kretz.de

indicated for use in conjunction with cataract surgery for the reduction of IOP in adult patients with mild-to-moderate primary open-angle glaucoma. It lowers IOP by creating a pathway for aqueous humor to drain directly from the anterior chamber into Schlemm's canal, bypassing the increased resistance of the trabecular meshwork. The iStent uses the same corneal incision used for cataract surgery, is not associated with the significant complications common to penetrating procedures and provides sustained and significantly reduced IOP. The pivotal FDA trial showed that phacoemulsification with stent implantation is more effective at controlling IOP than phacoemulsification alone. In fact, 75% of phaco/iStent patients were medication-free at one-year post-surgery.⁴

Advances in cataract surgery technology allow us to offer IOL options that can give patients outcomes never before possible. However, these IOLs require additional patient cost, and when patients make a greater investment, they have greater expectations. Premium IOL patients not only expect to be spectacle-free, they also expect a rapid and pain-free recovery. We realized that iStent patients could also be offered premium IOLs, as the micro-stent would in no way negatively affect their recovery time or comfort.⁵

The advancements of premium IOLs has enabled the patients to undergo a procedure to reduce or eliminate their need for glasses. The use of the iStent at the time of cataract surgery will allow surgeons to offer glaucoma patients a procedure to reduce or eliminate their need for glaucoma drops. By combining the procedures, we can now provide patients who suffer from cataracts and glaucoma an unprecedented combination. Phacoemulsification with premium IOL implantation in conjunction with iStent implantation may provide patients with a new possibility that will further enhance their vision and their lifestyle.

CASE REPORT

A 64-year-old female presented with diminution of vision in both eyes, trouble in driving at night with complaints of halo and glare, dry eye, asthenopia and black dots in visual field. She has known to have normal tension glaucoma (NTG) for two years. Past ocular history contains recurrent external hordeolum, blepharitis and dry eye syndrome. Several anti-glaucomatous eyedrops (prostaglandins, decarboxylase inhibitors and prostaglandin – timolol combinations) had been prescribed for lowering IOP and Hylo-COMOD and Systane for her dry-eye symptoms. Systemic diseases included: colitis and polyneuropathy. Before the operation patient had corrected distance visual acuity (CDVA) OD: 0,20 (LogMAR) and OS: 0,00 (LogMAR), the intraocular pressure OD:15 mmHg and OS: 17mmHg. Anterior segment examination showed:

cortical cataract in both eyes and irregularities in tear-film on both eyes. Central corneal thickness of 558 microns in OD and 554 microns in OS, Endothelial cell count for OD: 2132 cells/mm² and OS: 2288 cells/mm², Gonioscopy examination revealed open angle with no pathology, posterior segment examination showed mild disc cupping on both sides, intact macula with no retinal pathology.

The patient underwent preoperative examination and counseling for glaucoma and cataract surgery. As a preoperative assessment, when the decision to operate was taken, the patient underwent a complete examination, including manifest refraction, corneal tomography (Pentacam HD, Oculus, Germany), IOP, slit lamp examination, visual field (OCULUS Twinfield® 2), endothelial cell density, spectral domain biometry (IOLMaster 700, Carl Zeiss Meditec, Germany), funduscopy and OCT examination of posterior segment (Zeiss Cirrus 4000 HD-OCT) (Figure 1). Target refraction was chosen closest to emmetropia.

The IOL powers were calculated using the Barrett Suite for implantation of a rotational asymmetric, multifocal, one-piece IOL (Oculentis LS-313 MF-30) in OD and an enhanced depth of focus IOL (Oculentis LS-313 Comfort-MF 15) in OS.

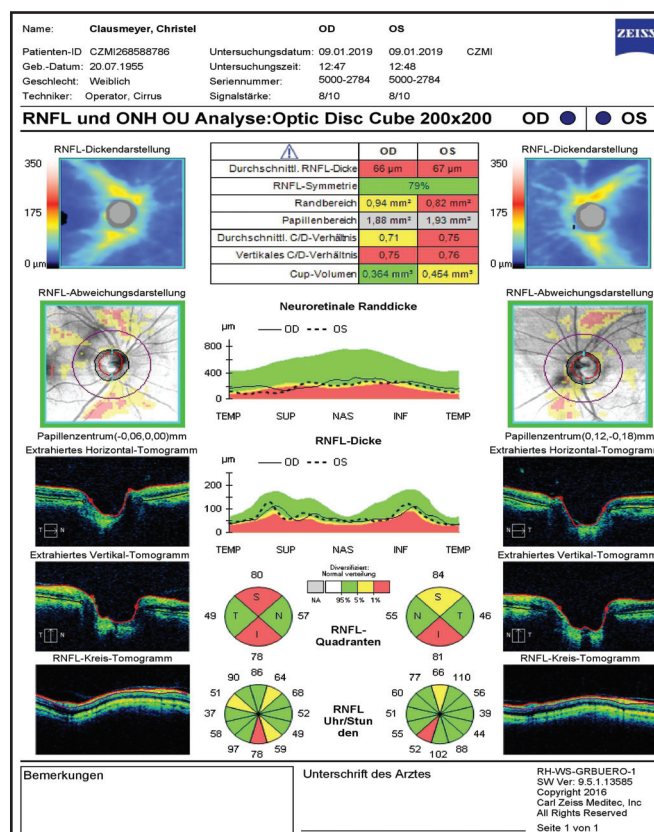


Figure 1: Retinal nerve fiber layer and Optic disc cube analysis shows atrophic changes of nerve fiber layer and optic disc cupping which are more prominent in the left eye.

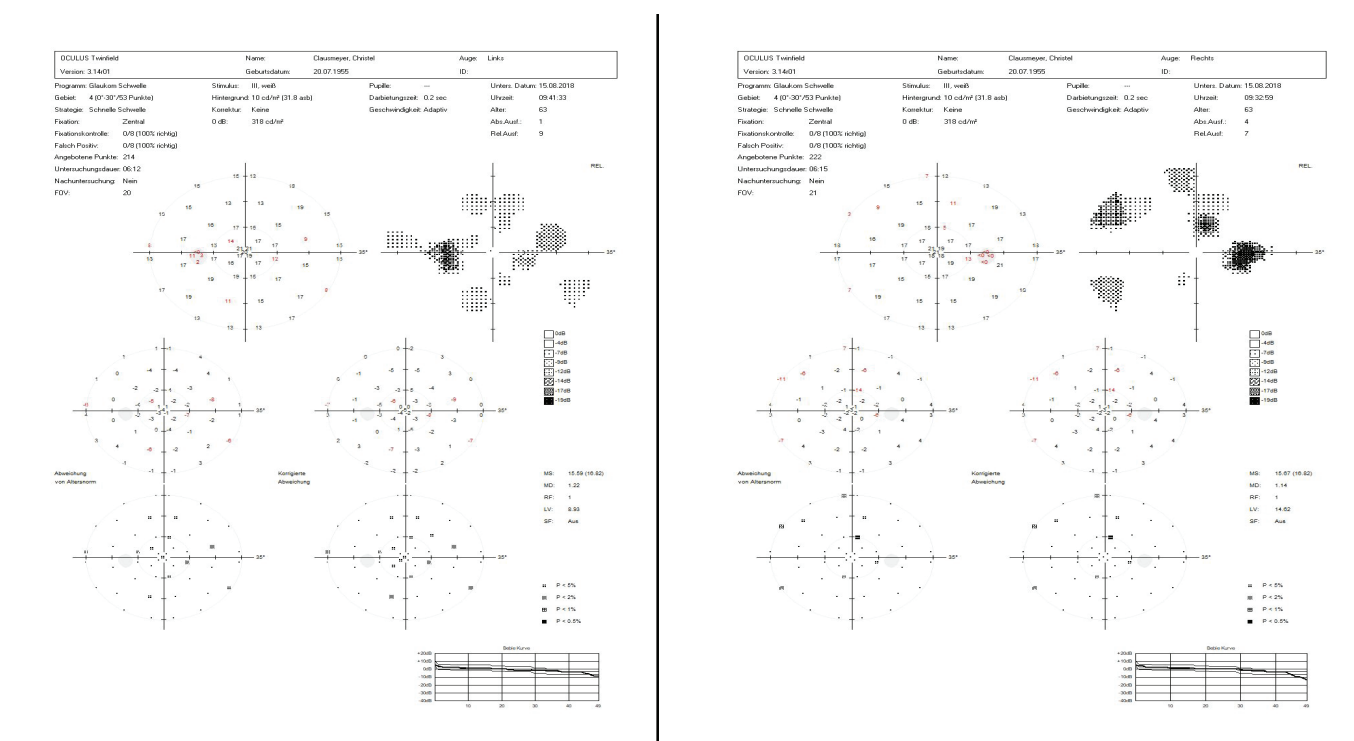


Figure 2: The visual field results of the patient, using the OCULUS Twinfield® 2, OS on the left side and OD on the right side.

A decision was made to perform a bilateral, simultaneous combined surgery with femtosecond-laser assisted cataract surgery combined with MIGS with two iStent inject® and phacoemulsification with intraocular lens (IOL) implantation in both eyes. Femtosecond laser-assisted cataract surgery was performed using the LensAR platform (LensAR Inc, USA). After uncomplicated surgery, the patient additionally received 0.05ml of 0.1mg/ml intravitreal dexamethasone for prophylaxis of cystoid macular edema and other possible inflammation. Postoperative dexamethasone and gentamicin eye drops were administered five times daily for one week.

After an uneventful operation, the post-operative intraocular

pressure was 15 mmHg for both eyes. 3 months after the surgery, patient presented with complains of having blurry, unsteady vision that fluctuates. Presence of the shadow in the right eye was more prominent than the left one.

We evaluated three months postoperative visual acuity monocular and binocular (UDVA, CDVA, DCIVA (90 cm), DCIVA (80 cm), DCIVA (60 cm), DCNVA (40 cm) and UNVA (40 cm) (Table 1), HD Analyzer (Visiometrics, USA) measurements (Table 2) Defocus curve (Figure 4) patient satisfaction (McAlinden), Halo and Glare Simulation (Halo and Glare Simulator Software, Carl Zeiss Meditec, Germany) (Figure 3).

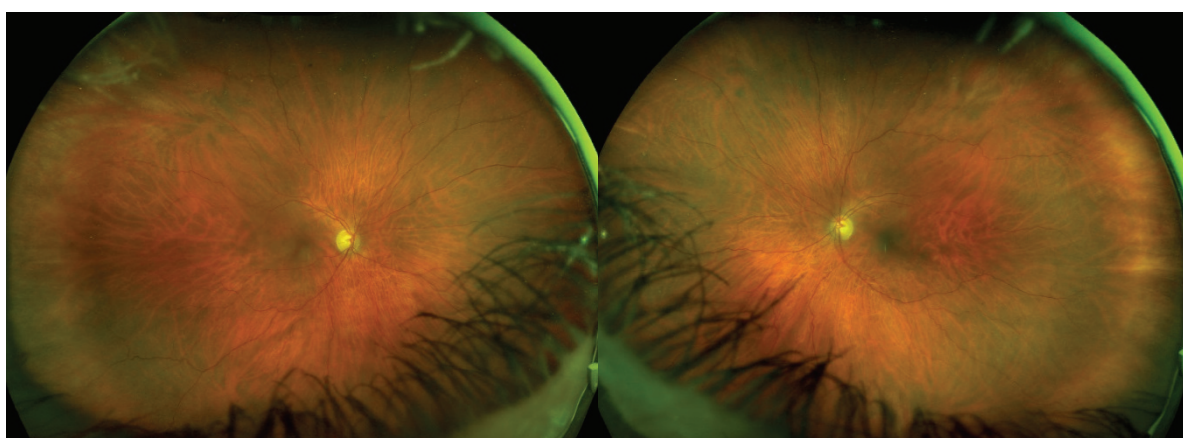


Figure 3: Fundus photographs of patient.

Table 1: Pre- and postoperative functional Results (CDVA: corrected distance visual acuity, UDVA: Uncorrected Distance Visual Acuity; DCIVA: Distance Corrected Intermediate Visual Acuity; DCNVA: Distance Corrected near Visual Acuity; UNVA: Uncorrected near Visual Acuity [logMAR]).

logMAR	Pre-Op			Post-OP		
	OD	OS	OU	OD	OS	OU
CDVA	0.2	0.0		-0.1	-0.1	-0.2
UDVA				-0.1	-0.1	-0.1
DICVA (90 cm)				0.14	-0.05	-0.05
DICVA (80 cm)				0.3	0	-0.1
DICVA (60 cm)				0.2	-0.1	0
DCNVA (40 cm)				0.1	0.3	0.2
UNVA (40 cm)				0.1	0.4	0.1

The 3-month post-operative objective analysis of optical quality using HD Analyzer™ (Visiometrics) results are described in (Table 2).

The monocular-defocus curve analysis for OD (MF-30 eye) showed visual acuity of 0,2 logMAR or better between

-2,25 D and +1,00 D of defocus, and 0,1 logMAR visual acuity was achieved in a range of -2,0 D to +0,75 D.

A visual acuity of 0,2 logMAR or better for OS (MF-15 eye) was achieved between -2,75 D and +1,00 D defocus. For OU a visual acuity of 0,2 logMAR or better was achieved between -2,5 D and +1,50 D defocus, and 0,0 logMAR or better was achieved in a range of -2,0 to +1,0 D.

Table 2: HD analyzer results 3-month post-operative.

Oculentis LS-313 MF-30					
	OSI		MTF cut off		Strehl ratio
OD	6		12,846		0,085
Oculentis standard LS-313 -MF 15					
	OSI		MTF cut off		Streh ratio
OS	3		18,348		0,111
MTFcut off (c/deg)	15	24	30	37.5	60
Snellen	20/40	20/25	20/20	20/16	20/10
Decimal	0.5	0.8	1.0	1.25	2.0

Postoperative and to evaluate the patient's satisfaction after surgery, a McAlinden questionnaire inquiring about the quality of vision for far, intermediate and near distance, the existence, and severity of halos and glare were evaluated. The patient reported seeing halos and starburst quite often and to a moderate intensity while having a blurry vision to a great extent. Vision fluctuation was quite often and noticeably, visual satisfaction for distance, intermediate and near was poor but she uses glasses only for near vision (Table 3).

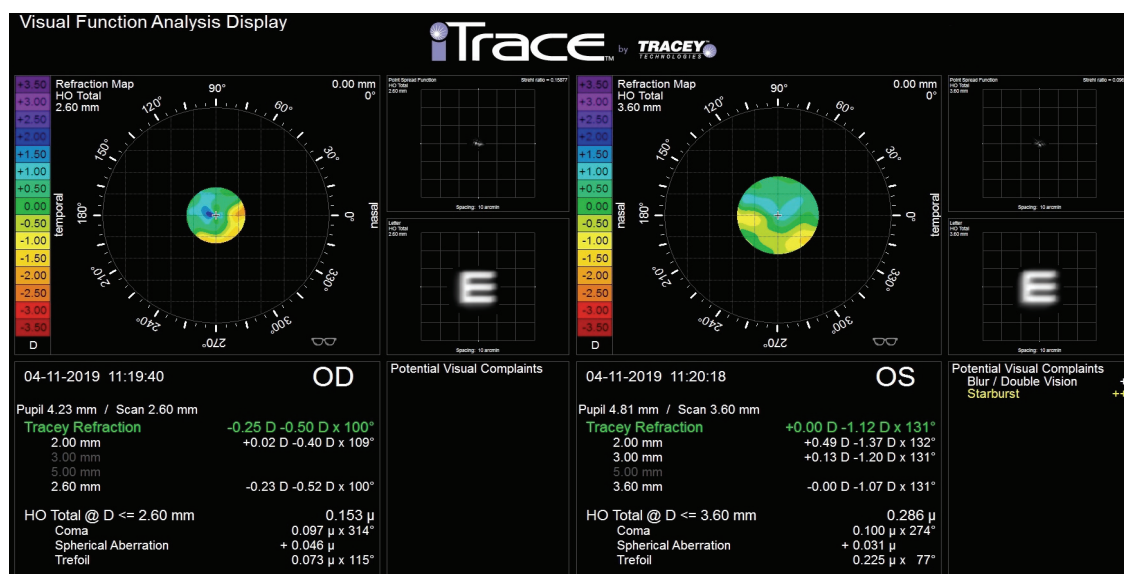


Figure 4: The post-operative results of iTrace visual function analysis from Tracey Technologies.

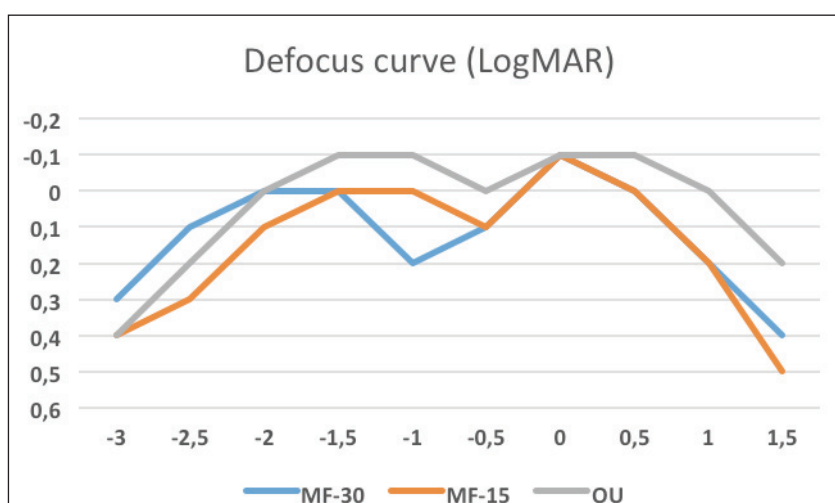


Figure 5: Defocus curve analysis.

Table 3: McAlinden questionnaire (Questions 1, 2, 4, 5, 8).		
Question n°1		
A- How often do you experience glare? Never Occasionally Quite often Very often	B- How severe is the glare? Not at all Mild Moderate Severely	C- How bothersome is the glare? Not at all A little Quite Very
Question n°2		
A-How often do you experience haloes? Never Occasionally Quite often Very often	B- How severe are the haloes? Not at all Mild Moderate Severely	C- How bothersome are the haloes? Not at all A little Quite Very
Question n°4		
A-How often do you experience hazy vision? Not at all A little Quite Very often	B- How severe is the hazy vision? Not at all Mild Moderate Severely	C- How bothersome is the hazy vision? Not at all A little Quite Very
Question n°5		
A- How often do you experience blurred vision? Not at all A little Quite Very often	B- How severe is the blurred vision? Not at all Mild Moderate Severely	C- How bothersome is the blurred vision? Not at all A little Quite Very
Question n°8		
A-How often do you experience a fluctuation in your vision? Not at all A little Quite Very often	B- How severe is the fluctuation in your vision? Not at all Mild Moderate Severely	C- How bothersome is the fluctuation in your vision? Not at all A little Quite Very

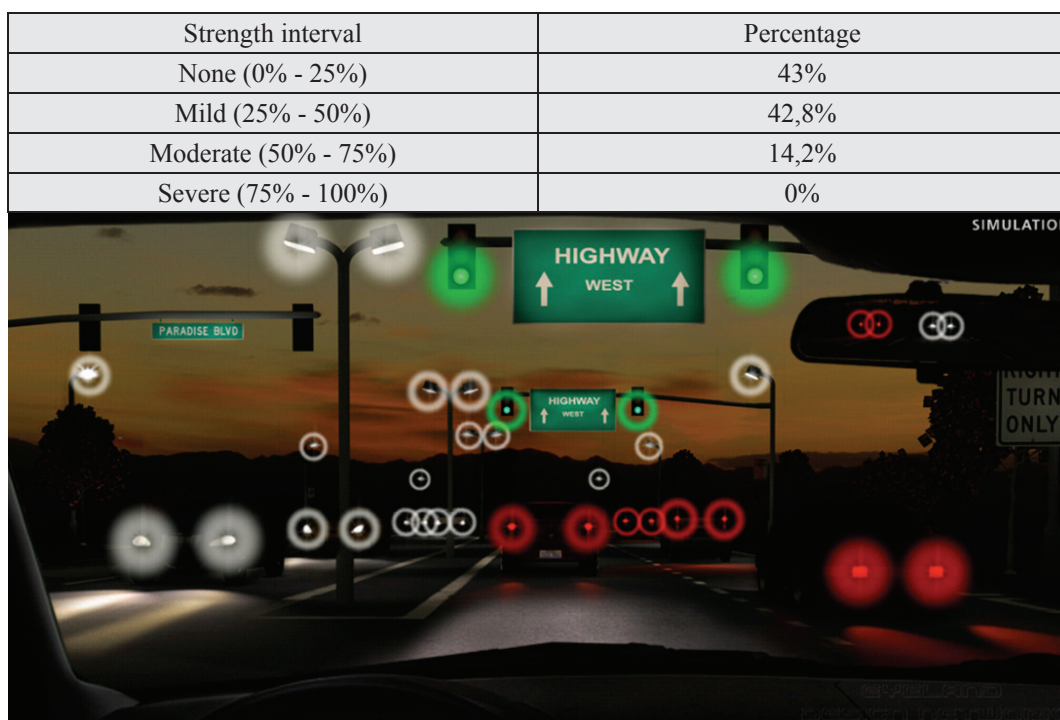


Figure 6: Halo and Glare Simulator results of what patient sees.

The corresponding Halo and Glare simulator settings showed halo strength of 62% and 0 % glare falling into moderate classification (figure 5).

DISCUSSION

Although subjective patient assessments of outcomes from refractive procedures remain the most important factor for surgeons, they also need to use objective measures to critically analyze outcomes from new technologies. The subjective success in patient satisfaction is a critical factor in surgeons clinical outcome measurements. We use subjective measurements, such as questionnaires, defocus curves, near visual acuity, or reading function. Such steps are needed to understand potential problems or why patients might be unsatisfied with the post-operative achieved results. Subjective measurements will always be as necessary as objective measurements.

In this patient, even though we achieved good objective outcomes as it is shown in table 1, but at the end of the day, the patient was unsatisfied with the sharpness of vision, halo and seeing a dark shadow on the temporal sides. The patient had evaporative dry eye disease and we assumed that the visual fluctuation and blurriness could be caused by abnormalities in tear-film. During the examination of tear-film, using HD-Analyzer (Visiometrics, TM), a tear break-up time of 3 seconds for the left eye and 10+ seconds in the right eye was recorded. We performed the intense pulsed light therapy on both eyes; the patient was instructed

to continue to use her artificial tears. Although the patient reported some improvement, she was not satisfied with the sharpness of her vision in general. For the management of dysphotopsia, pilocarpine 0,1% solution was prescribed for 1 month and the discontinued. Afterwards the patient was slightly more satisfied with her result.

There are three factors regarding patient's complaints about dysphotopsia: 1. what the patient actually sees, 2. how the patient reacts to the symptom, 3. the patient's reaction can be most significant factor for the management. The brain eventually in most cases adopts and eliminates unwanted visual input by the phenomenon of central adaptation.

Intraocular pressure (IOP) over 3 months postoperative for both eyes was 15 mmHg. No postoperative IOP spikes were noticed and the patient was quite happy that she will not use any eye drops for controlling the intraocular pressure.

CONCLUSION

Even with the best available measurements and formulas, refractive surprises can still occur. The ocular surface should be appropriately addressed in patients with glaucoma receiving a premium lens.

In the case of refractive dissatisfaction, management will depend on the patient's expectations. It is important to do the right things pre, intra and post-operatively and explain to the patient about possible surprises such as dysphotopsia.

Dysphotopsia may not result in an IOL exchange but will result in substantial additional chair time after uneventful surgery.

Phacoemulsification with premium IOL implantation in conjunction with iStent implantation shows promising results for both patients and surgeons. Patients with glaucoma or ocular hypertension with no visual field loss can be good candidates for presbyopia-correcting IOLs. Still the counseling can be difficult and even good functional results don't necessarily make our patients happy.

REFERENCES

- 1- Ronald C. Gentile, M., Brooke Nesmith, M., Kenneth J. Rosenthal, M., Richard B. Rosen, M., Emily C. Waisbren, M., H. Jay Wisnicki, M., & Joseph F. Panarelli, M. (2016, 01 06). Medscape. Retrieved from <https://www.medscape.com/viewarticle/873953>
- 2- Monali S. Malvankar-Mehta, Y. I. (2015, 06 06). iStent with Phacoemulsification: A Meta-Analysis. p. DOI:10.1371/journal.pone.0131770.
- 3- Carlos Buznego, M. (2010, 11). Eyeworld. Retrieved from <https://www.eyeworld.org/article-the-use-of-istent>
- 4- Carlos Buznego, M. (2010, 11). Eyeworld. Retrieved from <https://www.eyeworld.org/article-the-use-of-istent>
- 5- Carlos Buznego, M. (2010, 11). Eyeworld. Retrieved from <https://www.eyeworld.org/article-the-use-of-istent>