

# Complication Management in Adenoviral Keratoconjunctivitis: Review

Emine Esra Karaca<sup>1</sup>, Zarife Nurbanu Aynaci<sup>1</sup>, Ozlem Evren Kemer<sup>1</sup>

## ABSTRACT

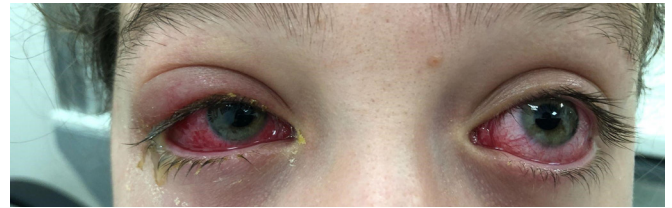
Adenoviral epidemic keratoconjunctivitis (EKC) is characterized by a significant inflammation of the conjunctiva and cornea, resulting in the potential formation of corneal opacities and impaired vision. These symptoms can endure for an extended period, lasting several months. Epidemic keratoconjunctivitis represents the most severe manifestation, as it affects the cornea and results in the formation of subepithelial infiltrates. As of now, there is no approved treatment specifically for adenoviral eye infections, so the current approach focuses on providing relief from symptoms. However complications such as subepithelial infiltrates and membranes could be relieved by careful treatment and follow-up. This review describes current management strategies for engaging the complications of adenoviral keratoconjunctivitis.

**Keywords:** Adenoviral keratoconjunctivitis, Subepithelial infiltrates, Tacrolimus.

## INTRODUCTION

Conjunctivitis is one of the most common conditions treated by ophthalmologists. Conjunctivitis can be infectious (viral, bacterial, etc) or noninfectious (allergic, mechanical, toxic, immune mediated, and neoplastic).<sup>1</sup> Adenoviral conjunctivitis is a major cause of acute infectious conjunctivitis cases among adults. Adenoviruses are highly contagious pathogens. The modes of transmission are mainly through hand to eye contact, ocular secretions, respiratory droplets, and contact with ophthalmic care providers and their medical instruments. Adenoviral infection is one of the leading causes of epidemic infections. The virus is very resistant to environmental conditions. The incubation period is 4 to 24 days. An infection usually starts at one eye and in 70% of cases the other eye is infected during the process and may be associated with bacterial superinfection (Figure 1).<sup>1</sup>

The most common manifestation of ocular adenoviral infection is epidemic keratoconjunctivitis (EKC), followed by pharyngoconjunctival fever (PCF). EKC is the severest form and presents with watery discharge, hyperemia,



**Figure 1:** Adenoviral keratoconjunctivitis: Usually starts one eye and in 70% of cases the other eye is also infected, associated with bacterial superinfection.

chemosis, and ipsilateral lymphadenopathy. PCF is characterized by sudden onset of high fever, bilateral conjunctivitis (Figure 2), pharyngitis and preauricular lymph node enlargement. Isolated follicular conjunctivitis also occurs without corneal or systemic involvement. The clinical accuracy rate in the diagnosis of viral conjunctivitis is less than 50%. The treatment of viral conjunctivitis is mostly supportive. The majority of cases are self-limited, and sometimes no specific treatment is necessary in uncomplicated cases.<sup>2</sup> Early detection and appropriate treatment is the key to expeditious resolution of the disease and helps minimize potential harmful effects or spread of untreated conjunctivitis.<sup>3</sup>

1- University of Health Sciences, Ankara Bilkent City Hospital, Department of Ophthalmology, Ankara, Türkiye

Received: 20.07.2023

Accepted: 23.07.2023

*J Glau-Cat 2023; 18: 99-105*

DOI: 10.37844/glau.cat.2023.18.14

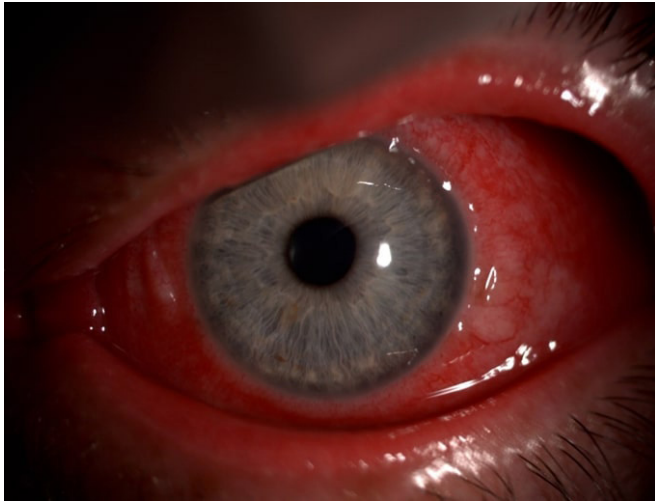
**Correspondence Address:**

Emine Esra Karaca

University of Health Sciences, Ankara Bilkent City Hospital, Department of Ophthalmology, Ankara, Türkiye

**Phone:**

**E-mail:** dreminesra@gmail.com



**Figure 2:** *Pharyngoconjunctival fever: Epiphora, eyelid swelling, burning, chemosis, conjunctival hyperemia, subconjunctival hemorrhage.*

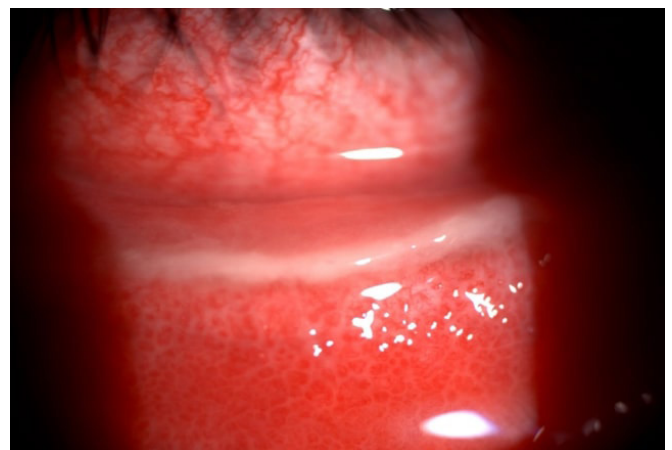
Adenoviral conjunctivitis is a self-limited disease that usually resolves completely within three weeks. Conservative treatments, including artificial lubricants and cool packs, can provide efficient symptomatic relief without any adverse effects. Topical antibiotics are utilized to treat or prevent bacterial superinfection.<sup>4</sup> Topical antihistamine eye drops and vasoconstrictors also reduce discomfort and duration of disease despite the risk of local toxicity.<sup>5</sup> The use of topical steroids is controversial. Topical steroids are frequently given in the acute phase, although this only has a temporary alleviating effect. The disease and infection durations could be prolonged due to increased adenovirus replication rate and extended viral shedding as demonstrated in animal models. Steroid treatment should be limited to complicated cases with pseudomembranes or subepithelial infiltrates where visual acuity is significantly reduced. Topical nonsteroidal anti-inflammatory drugs are also ineffective in controlling adenovirus replication in animal models.<sup>6</sup> Although nonsteroidal anti-inflammatory drugs have no significant effect on the subepithelial infiltrates, they may be a safer alternative to topical steroids for symptomatic relief. Virustatic agents such as vidarabine, trifluridine and ganciclovir are only mildly effective against adenovirus, and current data with regard to their efficacy in treating adenoviral conjunctivitis remains controversial.<sup>7</sup>

Epidemic keratoconjunctivitis, which is most commonly caused by adenoviral serotypes 8, 19, and 37, represents the most common external ocular viral infections. Adenoviral conjunctivitis is usually diagnosed on the basis of symptoms and clinical findings. Laboratory testing is

typically unnecessary, but can be helpful in confirming the diagnosis and diminishing healthcare costs. Testing includes cell culture, direct immunofluorescence, PCR and rapid antigen detection immunoassays. Rapid diagnostic tests may decrease unnecessary antibiotic usage.<sup>8</sup>

### COMPLICATIONS OF ADENOVIRAL KERATOCONJUNCTIVITIS

The formation of pseudomembranes (Figure 3), discs of fibrin-rich exudate lacking blood or lymphatic vessels adhered to the upper and lower tarsal conjunctiva, is a frequent complication in EKC, especially in infection associated with serotypes 8, 19, and 37. Pseudomembranes differ from true membranes in that they can be separated from the conjunctiva without damaging the underlying epithelium, thereby causing minor bleeding. Though it was traditionally taught that EKC is related with pseudomembranes rather than true membranes, a recent study on the membrane structure has shown that, apart from a conglomerate of leukocytes (including neutrophils, macrophages, T-cells, and activated dendritic cells) enmeshed in an eosinophilic extracellular matrix, there was formation of coagulum beneath the epithelium, early angiogenesis with the expression of angiogenic factors like vascular endothelial growth factor and transforming growth factor- $\beta$ , and existence of degenerative conjunctival epithelium. The latter suggests that true conjunctival membranes may form in EKC, depending on the degree and intensity of inflammation. Such true membranes, when removed, induce bleeding and their persistence may lead to subepithelial fibrosis and symblepharon formation. If there is membrane formation, debridement every 2 to 3 days and topical steroids can be used for treatment. Even with



**Figure 3:** *Epidemic keratoconjunctivitis: Patient with subconjunctival hemorrhages and pseudomembranes on the lower tarsal conjunctiva.*

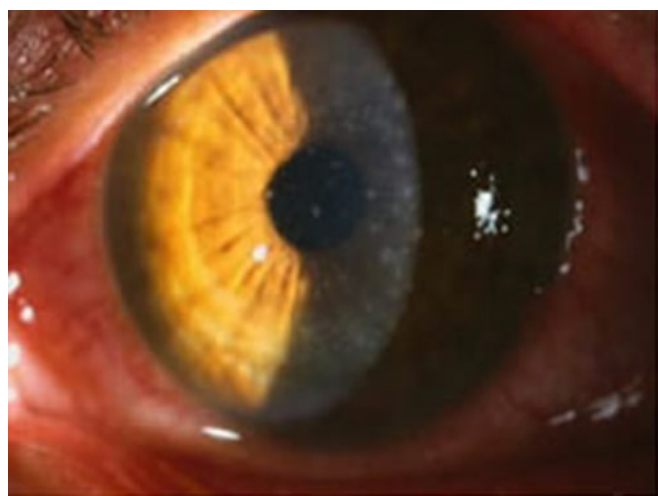supportive therapy, the intense conjunctival inflammatory response can lead to persistent symblepharon formation and dry eye.<sup>9</sup>

Bacterial superinfection in adenoviral conjunctivitis is uncommon, yet it can be severe in pediatric patients and lead to strabismus and amblyopia. The more commonly reported pathogens include gram-positive cocci, particularly *Streptococcus pyogenes*. Although infrequent, gram-negative rods have been identified in adenoviral conjunctivitis-related superinfections.<sup>10</sup>

### ***Subepithelial Infiltrates Secondary to Adenoviral Keratoconjunctivitis***

Keratitis, followed approximately ten days after the onset of the follicular conjunctivitis, can present with the formation of subepithelial corneal infiltrates (Figure 4) (SEIs) commonly bilaterally and usually asymmetric. Histologically, SEI have been shown to be collections of lymphocytes, histiocytes, and fibroblast that may be accompanied by disruption of the collagen fibers of Bowman layer.<sup>11</sup> The SEIs have the potential to cause significant ocular morbidity, reduced vision, glare, photophobia, halos, foreign body sensation, and may persist for months or years following the initial infection.<sup>12</sup> Accordingly, SEI and their associated symptoms may resolve with the use of topical corticosteroid eye drops, although they may often recur on discontinuation of therapy, even when tapered slowly.<sup>13</sup>

When used alone, topical steroid use is associated with longer periods of viral shedding and infection.<sup>14</sup>



**Figure 4:** *Epidemic keratoconjunctivitis - sequelae: With persistent pronounced central subepithelial corneal infiltrates with a free zone towards the limbus. Photophobia, visual impairment.*

The anti-inflammatory and immunosuppressive effect of corticosteroids are thought to inhibit normal virus clearance by the immune system. However, when used in combination with anti-infective agents, corticosteroids such as dexamethasone have been shown to be well tolerated and is effective in the treatment of inflammatory conditions associated with viral and bacterial infections.<sup>15-16</sup> The dexamethasone ophthalmic package insert warns that long-term use of topical dexamethasone may lead to ocular hypertension and/or glaucoma, posterior subcapsular cataract formation, and immune suppression with consequent risk of secondary ocular infections.<sup>17</sup> Published data have shown that when used in combination with antibiotics or antiseptics for 7 days, dexamethasone was well tolerated without a significant increase in IOP and without observed trend toward increase in viral shedding or viral titers.<sup>18-21</sup> Furthermore, when preservative-free dexamethasone 0.01% was used and follow-up was performed 4 to 60 months later, none of the patients had an IOP elevation of 5 mm-Hg above baseline, suggesting that short-term use of low-dose dexamethasone may be well tolerated.<sup>22</sup>

Cyclosporin A (CsA) has been used to prevent rejection of organ transplants for the past 20 years. It is an immunosuppressive agent that inhibits the transcription of interleukin-2 that leads to reduction in activity of T lymphocytes. A small clinical trial suggested a possible therapeutic role for topical CsA in the treatment of acute and chronic adenoviral infections.<sup>23</sup> One percent CsA administered 4 times a day for 21 days during the acute infection produced earlier subjective improvement of local symptoms and a trend toward a decrease in the incidence of corneal opacity.

In another study, the majority of patients with long standing established SEIs were successfully treated with 2% CsA with reduction or elimination of SEIs and successful discontinuation of therapy.<sup>24</sup>

According to Levinger et al, there was a significant reduction in the number of medications patients used after switching from topical steroids to topical Cyclosporine (CsA).

This was mainly because some of the patients responded to steroids and needed glaucoma medications to control their IOP. IOP was lower with CsA treatment, but this change wasn't statistically significant. Overall patient satisfaction and subjective improvement in vision with CsA was high. Topical CsA treatment provided significant relief of ocular



symptoms in all patients. This response of patients with SEIs to topical CsA may be attributed to its immunomodulatory effect by inhibiting T-cell proliferation and activity. CsA content has an excellent safety profile. Topical CsA carries none of the sight-threatening complications of topical steroids, such as glaucoma and cataract formation; as such, it may be a best first line of therapy for chronic SEI. The most common side effects reported were blurred vision, burning on instillation, allergic reaction to the oil solvent or CsA itself and lacrimation.<sup>25</sup>

Another promising agent in the treatment of SEI is topical tacrolimus. Topical tacrolimus, compounded in the pharmacy, appears to be an effective and safe option for the treatment of SEIs secondary to adenovirus keratoconjunctivitis. Tacrolimus, also known as FK506, is a macrolide derived from the soil fungus *Streptomyces tsukubaensis*. Tacrolimus has been reported to inhibit calcineurin 100 times more effectively than CsA and has shown efficacy in treating ocular pathology in several studies.<sup>26-29</sup> In addition, it has so far had an excellent safety profile in ophthalmic applications. The pharmacology of tacrolimus includes reduction of proinflammatory cytokines, activated T cells, and markers of apoptosis. Tacrolimus has been used “off label” in corneal transplant rejection, inflammatory conjunctival and corneal diseases (such as vernal keratoconjunctivitis, atopic keratoconjunctivitis, atopic keratoconjunctivitis, atopic blepharoconjunctivitis, or Mooren ulcers), uveitis, high-risk penetrating keratoplasty, and graft-versus-host disease.<sup>28-36</sup> In addition to its action against T-cell proliferation, in-vitro tacrolimus showed a direct inhibitory effect on mast-cell degranulation. It also appears to inhibit the production of the proinflammatory mediator, interleukin 8 (IL-8), and the IL-8 receptor, as well as to decrease the binding of IL-8 to its receptor on keratinocytes.<sup>35</sup> The results of invitro studies also suggested that tacrolimus enhances the effect of the tumor suppressor gene, p53.<sup>35</sup>

Tacrolimus ointment and drops can cause several side-effects, such as heat in the eye, eye irritation, pain, conjunctival hyperemia, and foreign body sensation.

In a study examining tacrolimus therapy in patients with atopic keratoconjunctivitis unresponsive to over 12 years of topical steroid and cyclosporine and systemic mast cell stabilizer and steroid therapy; eight weeks later, the patient returned with approximately 70% reduction in papillae size and objective improvement with respect to inflammation, no evidence of chemosis or corneal staining, only a discrete tarsal hyperemia.<sup>33</sup>

In another study that aimed to evaluate the therapeutic effects of dermatological tacrolimus ointment on the eyelids in the treatment of vernal keratoconjunctivitis; clinical signs and symptoms improved significantly after tacrolimus treatment. Significant reduction in papilla size, reduction in discharge, improvement of hyperemia and healing of thyroid ulcers with reepithelialization were observed in all patients. The patients' complaints about the treatment are only a slight burning sensation during the administration of the drug to the eyelids, and this sensation disappeared a few days after the treatment.<sup>32</sup>

According to another study, tacrolimus ointment and drops were found to be effective in the treating SEI.<sup>36</sup> The study included 85 eyes of 55 patients treated with tacrolimus 0.03% eye drops twice daily or 0.02% tacrolimus ointment once daily (at night). Although they did not observe differences in treatment response as measured by elimination or reduction of SEIs, an increase in visual acuity (VA) was observed in both groups.

The relapse rate observed in this study (18.8%) is consistent with or even better than previously described, between 20 and 30% after discontinuation of treatment. In terms of tolerability, they had observed more patients with blurring, irritation and itching in the tacrolimus ointment group than in the eye drops group with statistically significant differences. Patients reported blurred vision and foreign body sensation after using the tacrolimus eye drops/ointment, which usually lasted 5 to 15 minutes. In this study, tacrolimus 0.03% eye drops and tacrolimus 0.02% ointment were found to be effective in the treatment of SEIs after adenovirus conjunctivitis and tacrolimus was well tolerated in patients despite pruritus and chemosis, no significant side effects were observed and the eye drops are better tolerated than the ointment. Pharmacy-prepared tacrolimus can be used as long-term therapy to prevent recurrence of SEI and to prevent steroid dependence and complications.<sup>36</sup>

Levinger et al. reported that topical tacrolimus 0.03 % was safe and efficient in treating a small number of patients with SEIs.<sup>35</sup> In this study; there was a significant improvement in cohort mean logMAR BCVA (~2 Snellen lines, p=0.042) at the end of the 22-week course of treatment. None of this patients reported blinding lights, foreign body sensation or other ocular side-effects associated with topical tacrolimus treatment.<sup>35</sup>

In different study showing the benefit of tacrolimus in the treatment of steroid-resistant SEI<sup>36</sup>, all patients were

initiated with tacrolimus 0.03% twice or thrice a daily, as well as 0.5% loteprednol etabonate or 1% prednisolone three times a daily for 1 week, twice a day for 1 week, and once a day for 1 week. Tacrolimus was tolerated by 85.7% of the patients, all of whom showed regression of infiltrates and improvement in CDVA and other ocular symptoms.<sup>36</sup>

According to another study comparing the safety and efficacy of tacrolimus 0.03% ointment and 0.05% dexamethasone ointment in the treatment of SEI, tacrolimus 0.03% has been shown to be an effective alternative to dexamethasone 0.05% with a low relapse rate, but may cause burning and foreign body sensation in some patients.<sup>37</sup>

Povidone iodine (PVP-I) is used by ophthalmologists as an antiseptic. In another study; investigating the effectiveness of PVP; Adults with positive Rapid Pathogen Screening Adeno-Detector positive test 1:1:1 ratio PVP-I 0.6%/dexamethasone 0.1% PVP-I 0.6% or The vehicle was treated bilaterally 4 times a day (days 1-5) for 5 days.<sup>38</sup> Patients were evaluated on days 3, 6 and 12 (+1 day window). The results of study show that an ophthalmic suspension of PVP-I 0.6% and dexamethasone 0.1% is safe and well tolerated for the treatment of acute adenoviral conjunctivitis.

The combination of PVP-I and dexamethasone can treat both viral and bacterial conjunctivitis and also to address the inflammatory component of infectious conjunctivitis.<sup>38-45</sup> Various combinations of PVP-I/dexamethasone have been studied or are currently being investigated for the treatment of inflammatory conditions associated with ocular infections.

Recent studies investigating the efficacy of PVP-I 0.4%/dexamethasone 0.1% suspension are as follows:

Preclinical data in rabbit eyes showed that it reduced symptoms of adenovirus infection and was effectively reduces virus titers and duration of virus shedding.<sup>39</sup> In vitro studies showed that it was effectively kills all bacterial, Candida, and Fusarium isolates within 60 seconds of exposure.<sup>42</sup> In an open-label, uncontrolled, descriptive phase 2 study in presumed viral conjunctivitis, 8 of 9 eyes achieved clinical resolution by days 3/4, and no adverse events or increased duration of viral shedding were observed.<sup>41</sup> In a randomized, masked, controlled trial in acute viral conjunctivitis, the formulation shortened the disease duration, and no prolonged viral shedding or differences in IOP versus artificial tears were observed.<sup>39</sup>

Recent studies investigating the efficacy of PVP-I 1.0%/dexamethasone 0.1% suspension are as follows: In a randomized controlled study, it reduced symptoms and accelerated recovery among patients with adenoviral keratoconjunctivitis.<sup>40</sup>

Recent studies investigating the efficacy of PVP-I 0.6%/dexamethasone 0.1% suspension are as follows: In a randomized, placebo-controlled, phase 2 trial, improved clinical resolution and eradication of adenovirus in patients with acute adenovirus conjunctivitis.<sup>43</sup>

The combination of PVP-I 1.0% and dexamethasone 0.1% four times a daily can reduce symptoms and accelerate recovery in epidemic keratoconjunctivitis patients.<sup>43</sup>

Recent studies investigating the efficacy of PVP-I 0.6%/dexamethasone 0.1% suspension are as follows :ophthalmic suspension used for 14 days had a favorable safety profile and was generally well tolerated.<sup>44</sup>

According to another study, use of PVP-I 2% in the early days of adenoviral keratoconjunctivitis may help reduce the risk of SEI as a complication.<sup>45</sup>

In the literature, there is a study in which an increase in visual acuity, improvements in photophobia and contrast sensitivity was observed in patients treated with mitomycin C and Phototherapeutic Keratectomy (PTK) in the treatment of SEI.<sup>46-47</sup> PTK is an effective method for treating corneal opacity after epidemic keratoconjunctivitis, resulting in a significant improvement in visual acuity and quality of vision (Higher-Order Aberrations).<sup>48</sup> The use of topical MMC in combination with photorefractive keratectomy (PRK) for the treatment of subepithelial infiltrates has shown good visual and refractive results.<sup>49</sup>

## CONCLUSION

Adenoviral conjunctivitis is a self-limiting disease, and the absence of an effective antiviral in its treatment has led to the use of various drugs in the treatment of disease-related complications. No specific treatment has been established for SEI and pseudomembranes. However, treatment management is important because it reduces the quality of vision . Pseudomembranes cause meibomian gland dysfunction which causes dry eyes. Topical steroids have a relaxing effect, the fact that the use of steroids in the early period increases active replication, increases intraocular pressure and causes cataract formation has led to the search for alternative treatments in SEI. Topical 2%

cyclosporin has been an alternative for the treatment of subepithelial infiltrates in the acute phase of infection, but results, side effects and relapse rates have been comparable to corticosteroids. According to recent studies, topical tacrolimus is safe with a low side-effect profile and is successful in the treatment of complications of adenoviral keratoconjunctivitis.

## REFERENCES

1. American Academy of Ophthalmology Cornea/External Disease Preferred Practice Pattern Panel. Preferred Practice Pattern Guidelines: Conjunctivitis. 2018. www.aao.org/ppp.
2. Jhanji V, Chan T, Li E, et al. Major review Adenoviral keratoconjunctivitis. *Surv Ophthalmol*. 2015;60:435-43.
3. Holland E, Fingeret M, Mah F. Use of Topical Steroids in Conjunctivitis: A Review of the Evidence. *Cornea*. 2019;38:1062-7.
4. Isenberg SJ, Apt L, Valenton M, et al. A controlled trial of povidone-iodine to treat infectious conjunctivitis in children. *Am J Ophthalmol*. 2002;134: 681-8.
5. Majeed A, Naem Z, Khan DA, et al. Epidemic adenoviral conjunctivitis report of an outbreak in a military garrison and recommendations for its management and prevention. *J Pak Med Assoc*. 2005;55:273-5.
6. Romanowski EG, Gordon YJ. Effects of diclofenac or ketorolac on the inhibitory activity of cidofovir in the Ad5/NZW rabbit model. *Invest Ophthalmol Vis Sci*. 2001;42:158-62.
7. Trousdale M, Goldschmidt PL, Nobrega R, et al. Activity of ganciclovir against human adenovirus type-5 infection in cell culture and cotton rat eyes. *Cornea*. 1994;13: 435-9.
8. Udeh BL, Schneider JE, Ohsfeldt RL. Cost effectiveness of a point-of-care test for adenoviral conjunctivitis. *Am J Med Sci*. 2008;336:254-64.
9. Chintakuntlawar AV, Chodosh J. Cellular and tissue architecture of conjunctival membranes in epidemic keratoconjunctivitis. *Ocul Immunol Inflamm*. 2010;18:341-5.
10. Gunther R. Pathologisch-anatomischer befund einer hornhaut bei keratitis epidemica. *Klin Monatsbl Augenheilkd*. 1939;103:309-14.
11. Hillenkamp J, Reinhard T, Ross RS, et al. Topical treatment of acute adenoviral keratoconjunctivitis with 0.2% cidofovir and 1% cyclosporine: a controlled clinical pilot study. *Arch Ophthalmol*. 2001;119:1487-91.
12. Laibson PR, Dhiri S, Oconer J, et al. Corneal infiltrates in epidemic keratoconjunctivitis. Response to double-blind corticosteroid therapy. *Arch Ophthalmol*. 1970;84:36-40.
13. Sundmacher R, Engelskirchen U. Recurrent and persistent nummuli after epidemic keratoconjunctivitis. *Klin Monatsbl Augenheilkd*. 1991;198: 550-4.
14. Romanowski EG, Roba LA, Wiley L, et al. The effects of corticosteroids of adenoviral replication. *Arch Ophthalmol*. 1996;114:581-5.
15. Faraldi F, Papa V, Rasà D, et al. Netilmicin/dexamethasone fixed combination in the treatment of conjunctival inflammation. *Clin Ophthalmol*. 2013;7:1239-44.
16. Maxidex [package insert]. Fort Worth, TX: Alcon Laboratories, Inc.; 2002.
17. Belfort R Jr, Gabriel L, Martins Bispo PJ, et al. Safety and efficacy of moxifloxacin-dexamethasone eyedrops as treatment for bacterial ocular infection associated with bacterial blepharitis. *Adv Ther*. 2012;29: 416-26.
18. Pinto RD, Lira RP, Abe RY, et al. Dexamethasone/povidone eye drops versus artificial tears for treatment of presumed viral conjunctivitis: a randomized clinical trial. *Curr Eye Res*. 2015;40:870-7.
19. Pelletier JS, Stewart K, Trattler W, et al. A combination povidone-iodine 0.4%/dexamethasone 0.1% ophthalmic suspension in the treatment of adenoviral conjunctivitis. *Adv Ther*. 2009;26:776-83.
20. Jonisch J, Steiner A, Udell IJ. Preservative-free low-dose dexamethasone for the treatment of chronic ocular surface disease refractory to standard therapy. *Cornea*. 2010;29:723-6.
21. Kilic A, Gurler B. Topical 2% cyclosporine A in preservative-free artificial tears for the treatment of vernal keratoconjunctivitis. *Can J Ophthalmol*. 2006;41:693-8.
22. Reinhard T, Godehardt E, Pfahl HG, et al. [Local cyclosporin A in nummuli after keratoconjunctivitis epidemica. A pilot study]. *Ophthalmologie*. 2000;97:764-8.
23. Levinger E, Slomovic A, Sansanayudh W, et al. Topical Treatment With 1% Cyclosporine for Subepithelial Infiltrates Secondary to Adenoviral Keratoconjunctivitis. *Cornea*. 2010;29:638-40.
24. Levinger E, Trivizki O, Shachar Y, et al. Topical 0.03 % tacrolimus for subepithelial infiltrates secondary to adenoviral keratoconjunctivitis. *Graefes Arch Clin Exp Ophthalmol*. 2014;252:811-6.
25. Ghanem RC, Vargas JF, Ghanem VC. Tacrolimus for the treatment of subepithelial infiltrates resistant to topical steroids after adenoviral keratoconjunctivitis. *Cornea*. 2014;33:1210-3.
26. Fukushima A, Ohashi Y, Ebihara N, et al. Therapeutic effects of 0.1% tacrolimus eye drops for refractory allergic ocular diseases with proliferative lesion or corneal involvement. *Br J Ophthalmol*. 2014;98:1023-7.
27. Dhaliwal JS, Mason BF, Kaufman SC. Long-term use of topical tacrolimus (FK506) in high-risk penetrating keratoplasty. *Cornea*. 2008;27:488-93.
28. Zhai J, Gu J, Yuan J, et al. Tacrolimus in the treatment of ocular diseases. *BioDrugs*. 2011;25:89-103.
29. Yamazoe K, Yamazoe K, Yamaguchi T, et al. Efficacy and safety of systemic tacrolimus in high-risk penetrating keratoplasty after graft failure with systemic cyclosporine. *Cornea*. 2014;33:1157-63.
30. Liu F, Liu H, Chu H, et al. Dermatologic tacrolimus ointment on the eyelids for steroid-refractory vernal keratoconjunctivitis. *Graefes Arch Clin Exp Ophthalmol*. 2019;257:967-74.
31. García D, Alperter J, Cristóbal J, et al. Topical Tacrolimus Ointment for Treatment of Intractable Atopic Keratoconjunctivitis: A Case

- Report and Review of the Literature. *Cornea*. 2011 ;30:462-5.
32. Sakassegawa-Naves F, Ricci H, Moscovici B, et al. Tacrolimus Ointment for Refractory Posterior Blepharitis. *Curr Eye Res*. 2017;42:1440-4.
  33. Lauerma AI, Granlund H, Reitamo S. Use of the newer immunosuppressive agents in dermatology. *BioDrugs*. 1997;8:96-106.
  34. Prado S, Ayora A, Fernández C, et al. Topical Tacrolimus for Corneal Subepithelial Infiltrates Secondary to Adenoviral Keratoconjunctivitis. *Cornea* 2017; 36:1102-5.
  35. Levinger E, Trivizki O, Shachar Y, et al. Topical 0.03 % tacrolimus for subepithelial infiltrates secondary to adenoviral keratoconjunctivitis . *Graefes Arch Clin Exp Ophthalmol*. 2014;252:811-6.
  36. Ghanem R, Vargas J, Ghanem V, et al. Tacrolimus for the Treatment of Subepithelial Infiltrates Resistant to Topical Steroids After Adenoviral Keratoconjunctivitis. *Cornea* 2014;33:1210-3.
  37. Bhargava R, Kumar P . Comparison of the safety and efficacy of topical Tacrolimus (0.03%) versus dexamethasone (0.05%) for subepithelial infiltrates after adenoviral conjunctivitis. *Indian J Ophthalmol* 2019;67:594-8.
  38. Pepose J, Ahuja A, Liu W, et al. Randomized, Controlled, Phase 2 Trial of Povidone-Iodine/Dexamethasone Ophthalmic Suspension for Treatment of Adenoviral Conjunctivitis. *Am J Ophthalmol*. 2018 ;194:7-15.
  39. Clement C, Capriotti JA, Kumar M, et al. Clinical and antiviral efficacy of an ophthalmic formulation of dexamethasone povidone-iodine in a rabbit model of adenoviral keratoconjunctivitis. *Invest Ophthalmol Vis Sci*. 2011;52:339-44.
  40. Pelletier JS, Miller D, Liang B, et al. In vitro efficacy of a povidone-iodine 0.4% and dexamethasone 0.1% suspension against ocular pathogens. *J Cataract Refract Surg*. 2011;37:763-6.
  41. Pelletier JS, Stewart K, Trattler W, et al. A combination povidone-iodine 0.4%/dexamethasone 0.1% ophthalmic suspension in the treatment of adenoviral conjunctivitis. *Adv Ther*. 2009;26:776-83.
  42. Pinto RD, Lira RP, Abe RY, et al. Dexamethasone/povidone eye drops versus artificial tears for treatment of presumed viral conjunctivitis: a randomized clinical trial. *Curr Eye Res*. 2015;40:870-7.
  43. Kovalyuk N, Kaiserman I, Mimouni M, et al. Treatment of adenoviral keratoconjunctivitis with a combination of povidone-iodine 1.0% and dexamethasone 0.1% drops: a clinical prospective controlled randomized study. *Acta Ophthalmol*. 2017;95 :e686-e692.
  44. Pepose JS, Ahuja A, Liu W, et al. Randomized, controlled, phase 2 trial of povidone-iodine/dexamethasone ophthalmic suspension for treatment of adenoviral conjunctivitis. *Am J Ophthalmol*. 2018;194:7-15.
  45. Pepose J, Narvekar A, Liu W, et al. A randomized controlled trial of povidone-iodine/dexamethasone ophthalmic suspension for acute viral conjunctivitis. *Clin Ophthalmol*. 2019;13:535-44.
  46. Labib B, Minhas B, Chigbu D et al. Management of Adenoviral Keratoconjunctivitis: Challenges and Solutions. *Clinical Ophthalmology* 2020;14: 837-52.
  47. Amazaki E, Ferraz C, Hazarbassanov R, et al. Phototherapeutic Keratectomy for the Treatment of Corneal Opacities After Epidemic Keratoconjunctivitis. *Am J Ophthalmol* 2011;151: 35-43.
  48. Yildiz B, Urvasizoglu S, Yildirim Y, et al. Changes in Higher-Order Aberrations After Phototherapeutic Keratectomy for Subepithelial Corneal Infiltrates After Epidemic Keratoconjunctivitis. *Cornea* 2017;36:1233-6.
  49. Alevi D, Barsam A, Kruh J, et al. Photorefractive keratectomy with mitomycin-C for the combined treatment of myopia and subepithelial infiltrates after epidemic keratoconjunctivitis. *J Cataract Refract Surg* 2012; 38:1028-33.